



Clinical Research

Feasibility of freehand MRI/US cognitive fusion transperineal biopsy of the prostate in local anaesthesia as in-office procedure—experience with 400 patients

Christian Wetterauer¹ · Osama Shahin² · Joel R. Federer-Gsponer¹ · Nicola Keller³ · Stephen Wyler⁴ · Hans Helge Seifert¹ · Maciej Kwiatkowski⁴

Received: 16 October 2019 / Revised: 17 December 2019 / Accepted: 19 December 2019

© The Author(s), under exclusive licence to Springer Nature Limited 2020

Abstract

Background Transrectal (TR) ultrasound-guided prostate biopsy is one of the most commonly performed urologic procedures worldwide. The major drawback of this approach is the associated risk for infectious complications. Sepsis rates are increasing due to rising antibiotic resistance, representing a global issue. The transperineal (TP) approach for prostate biopsy has recently been adopted at many centres as an alternative to the TR biopsy, and it was shown to be associated with a lower risk for sepsis. The aim of this study was to assess safety and tolerability of TP prostate biopsy performed in local anaesthesia.

Methods We retrospectively analysed data of patients who had undergone office-based TP prostate biopsy in local anaesthesia, performed by a single surgeon between January 2015 and May 2019. We evaluated the patients' acceptance of the procedure by a pain score, as well as its safety and diagnostic performance.

Results Four hundred patients were included. Median age was 66 years [range, 49–86]. Median prostate-specific antigen (PSA) concentration was 6.4 ng/ml [range, 0.3–1400], median PSA density was 0.15 ng/ml² [range, 0–31.1] and median prostate volume was 40 ml [range, 6–150]. A total of 118 (29.5%) and 105 (26.2%) patients had orally received two and one doses of 500 mg fluoroquinolone, respectively, and 177 (44.3%) patients did not receive any antibiotic prophylaxis. No infectious complications occurred. Median pain score was 2.0 (range, 0–8). Overall cancer detection rate was 64.5% (258/400).

Conclusions Freehand TP prostate biopsy in local anaesthesia is a safe, effective and well-tolerated outpatient procedure with a high cancer detection rate. The elimination of infectious complications and its high accuracy make this technique a feasible alternative to the TR approach for the urological office. We assume that the single puncture and our trocar-like access sheath introduction technique diminish tissue trauma and bacterial exposition, and thus contribute to these promising results.

Introduction

Prostate cancer (PCa) is the most common cancer in men [1]. Due to demographic developments and an increase of aggressive tumours in younger patients, PCa nowadays is ranked as second leading cause for male cancer death [2]. New diagnostic technologies like multi-parametric magnetic resonance imaging (mpMRI) enable improved detection of clinically relevant PCa. Therefore, MRI-targeted prostate biopsy (PBx) currently represents the standard method for PCa diagnosis. PBx can be performed via a transrectal (TR) or a transperineal (TP) approach, both of which have advantages and disadvantages. TR PBx can be performed under local anaesthesia (LA) in an outpatient setting and

✉ Christian Wetterauer
christian.wetterauer@usb.ch

¹ Department of Urology, University Hospital Basel, Basel, Switzerland

² Uro Merian, Basel, Switzerland

³ University of Basel, Basel, Switzerland

⁴ Department of Urology, Cantonal Hospital Aarau, Aarau, Switzerland

Table 1 Perioperative antibiotic prophylaxis and prevalence of infectious complications.

Perioperative antibiotic prophylaxis	<i>n</i> (%)	Prevalence of infectious complications (%)
Two doses of 500 mg fluoroquinolone	118 (29.5%)	0
One dose of 500 mg fluoroquinolone	105 (26.3%)	0
No antibiotic prophylaxis	177 (44.3%)	0

therefore represents the standard in-office technique. In the US, the overwhelming majority of biopsies are performed via a TR approach (93.1–99.2%) [3]. Due to the passage of needles through the rectum, patients are at risk for infectious complications. The incidence of cystitis, prostatitis, epididymitis and sepsis ranges between 5 and 7%. Admission rates of up to 2% are reported, despite the use of antibiotic prophylaxis [4–6]. Infection rates after TP PBx are significantly lower [7, 8]. However, TP PBx is usually performed under general or spinal anaesthesia. Recent cost analyses comparing TP PBx under general anaesthesia to TR PBx demonstrated 153% higher costs for the TP procedure [9]. Therefore, TP PBx is considered not suitable as an “in-office procedure”, and the associated logistic barrier (need for general or spinal anaesthesia) has impeded its widespread use [10]. Accordingly, the percentage of TP PBx performed in the US during the period between 2009 and 2017 is stagnating well below 1% [3]. Furthermore, MRI-targeted PBx requires specialised training and software based biopsy systems. Free-hand cognitive fusion techniques, however, may represent an alternative method for the in-office application [11]. Current results could demonstrate excellent cancer detection rates via perineal approaches, most probably due to the easier access and detection of anterior tumours [12, 13].

Performing TP PBx under an LA is combining all benefits of the two approaches. First evidence already suggests that TP PBx using an LA represents a viable alternative to TR PBx [11, 14–16]. Currently, efforts are made to improve the safety and tolerability of TP PBx under an LA by using specialized cannulas [11, 15, 16].

The aim of this study was to evaluate a series of TP PBx under an LA in terms of safety, tolerability and feasibility as an in-office procedure. Furthermore, we assessed the cancer detection rates of free-hand cognitive fusion biopsy.

Patients and methods

Four hundred patients who underwent perineal PBx at Uro Merian, Basel, between January 2015 and May 2019 were enrolled in this retrospective study. Demographic and clinical data, such as antibiotic prophylaxis, mpMRI findings and number of biopsies, as well as histopathologic findings were extracted by chart review. This study was approved by the

local ethical commission IRB (EKNZ 2019–01208). Three hundred and eight (77%) of the patients had undergone mpMRI prior to biopsy. All biopsies were performed by a single surgeon (OS), assisted by his care assistant. The first 118 (29.5%) patients in this cohort have received two doses of 500 mg fluoroquinolone orally. The first dose was taken in the evening prior to PBx and the second dose was taken 1 h before the biopsy. The next 105 (26.2%) patients have received only a single dose of 500 mg fluoroquinolone one hour before the biopsy. Since June 2017, we have fully abstained from antibiotic prophylaxis, wherefore the remaining one hundred and seventy-seven (44.3%) patients had received no antibiotic prophylaxis, unless otherwise indicated (Table 1).

All imaging was performed with 3 T MRI scanners. During the first phase of the study, Prostate Imaging-Reporting and Data System (PI-RADS) (v.1) was applied for the evaluation of prostate MRI. After publication of PI-RADS (v.2) in January 2016, the updated version was used. We compared the overall cancer detection rates during these two periods in order to examine whether the two versions of the PI-RADS would result in significantly different cancer detection rates.

Technique

The patients were placed in lithotomy position, the perineum was disinfected and a rectal ultrasound probe (linear probe, 7.5 MHz, Arietta V70, Hitachi) was introduced. On each side of the midline, 10 ml of LA (1% lidocaine) was applied to the perineal skin and the subcutaneous tissue, as well as to the pelvic floor under ultrasonic guidance. A 16-Gauge (1.6 mm) needle was then introduced into the numb skin and used as an access sheath for the biopsy gun (Corazor 18GA/1,20–240 mm, Uromed). Optimal skin entry points were chosen 45° ventral and 1.5 cm from the anus (Fig. 1) as described by Emiliozzi et al. [17].

This allowed targeting any area of the prostate, thus enabling both systematic and cognitive MRI/US fusion biopsy (Fig. 2). The standard random biopsy template comprised 12 biopsy cores. The number of biopsies taken was adapted to the individual prostate volume. In case of suspicious lesions in mpMRI (\geq PI-RADS 3), an additional targeted biopsy was performed. Generally, two biopsy cores per identified lesion were taken.

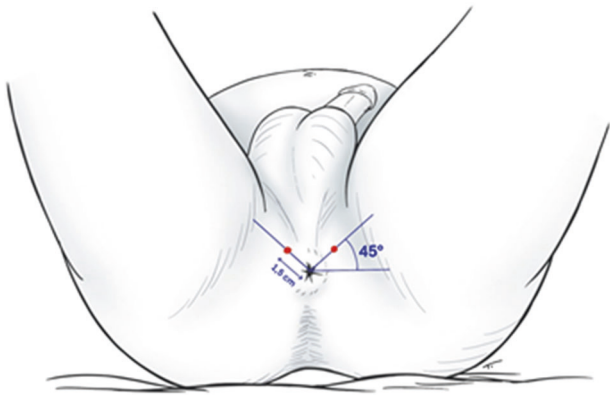


Fig. 1 The patients are placed in lithotomy position. Optimal entry points are chosen 45° ventral and 1.5 cm from the anus as described by Emiliozzi et al. [17]. A 16-Gauge (1.6 mm) needle functions as an access sheath for the biopsy gun.

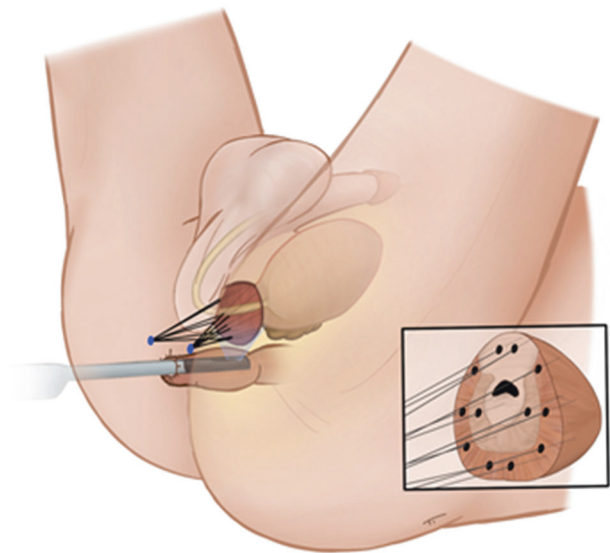


Fig. 2 The two perineal entry points allow to biopsy all areas of the prostate under transrectal ultrasound guidance. The fan technique enables to obtain biopsies from the whole gland and make especially anterior targets easily accessible.

A visual analogue scale (VAS) ranging from 0 to 10 was used to record the pain perceived by the patients during the procedure. We used the Clavien Dindo grading system [18] to classify clinically relevant complications such as urinary retention and infectious complications occurring after PBx. Other complications, such as gross haematuria or haematospermia, were self-limiting in all patients and were not assessed systematically, as a meta-analysis [19] has already demonstrated no significantly different prevalence for TR and TP approaches.

All statistical inference testing and data visualisation was performed using R 3.0.1. Ordinal and continuous data were analysed using a chi-square test and a non-parametric Mann–Whitney U test, respectively. Non-normality

Table 2 Baseline characteristics.

Age in years, median [range]	66 [49–86]
Prostate volume in ml, median [range]	40 [6–150]
PSA in ng/ml, median [range]	6.4 [0.3–1400]
PSA density in ng/ml ² , median [range]	0.15 [0–31.1]
Median number of total biopsies, median [range]	13 [4–20]
First biopsy, <i>n</i> (%)	284 (71%)
Re-biopsy, <i>n</i> (%)	77 (19.3%)
Multiple prior biopsies, <i>n</i> (%)	39 (9.8%)

Spearman's correlation tests were performed to determine the associations between different independent variables. All tests were performed at a significance level of $\alpha = 0.05$. Data are presented as medians with the maximum range.

Results

The median age was 66 years [range, 49–86]. Median prostate-specific antigen (PSA) concentration was 6.4 ng/ml [range, 0.3–1400], median PSA density was 0.15 ng/ml² [range, 0–31.1] and median prostate volume was 40 ml [range, 6–150] (Table 2). Multi-parametric MRI of the prostate revealed a total of 266 lesions suspicious for PCA. Thirty-one (11.7%) of these lesions were classified as PI-RADS 3, 172 (64.7%) as PI-RADS 4 and 63 (23.7%) as PI-RADS 5 (Table 3). In 266 (66.5%) of the 400 patients, the TP random biopsy was performed in combination with freehand MRI/US cognitive fusion; the remaining 134 (33.5%) of the patients underwent the TP random biopsy only. The median number of cores taken was 13 [range, 4–20]. Two hundred and eighty-four (71%) of the patients were biopsy naïve, 77 (19.3%) underwent re-biopsy and 39 (9.8%) had undergone two or more biopsies previously (Table 2). Median VAS score for pain was 2 [range, 0–8]. We could detect a significant correlation of age with perceived pain: older men perceived less pain than younger individuals ($p < 0.01$). Prostate volume and total number of biopsies did not correlate with the perceived pain during the procedure ($p > 0.05$). None of the patient required additional analgesics or LA. None of the PBx had to be interrupted due to discomfort or pain. Twenty-three (54.8%) of 42 men who had undergone prior TR PBx rated TP PBx as the less painful procedure, 15 (35.7%) reported no difference and 4 of 42 (9.5%) preferred TR PBx over TP PBx. No periprocedural complications occurred. Four (1%) of the overall 400 patients developed acute urinary retention after biopsy and required temporary catheterisation (Clavien Dindo Grade 1). Infectious complications occurred neither in the group of patients who had received antibiotic prophylaxis nor in the group who had received no antibiotic prophylaxis

Table 3 Cancer detection rates.

	Overall	Gleason 6 ISUP Grade 1	Gleason 7a ISUP Grade 2	Gleason 7b ISUP Grade 3	Gleason 8 ISUP Grade 4	Gleason 9 and 10 ISUP Grade 5
All cases (<i>n</i> = 400)	258 (64.5%)	43 (16.7%)	113 (43.8%)	71 (27.5%)	20 (7.8%)	11 (4.3%)
Cases with PI-RADS 3 (<i>n</i> = 31)	14 (45.1%)	7 (23.3%)	3 (6.4%)	3 (6.4%)	1 (7.1%)	0 (0%)
Cases with PI-RADS 4 (<i>n</i> = 172)	107 (62.2%)	21 (70%)	57 (68.7%)	20 (42.6%)	7 (50%)	2 (28.6%)
Cases with PI-RADS 5 (<i>n</i> = 63)	59 (93.7%)	1 (3.3%)	23 (27.7%)	24 (51.1%)	6 (42.9%)	5 (71.4%)

(Clavien Dindo Grade 0) (Table 1). Overall cancer detection rate was 64.5% (258 of 400 patients). The application of PI-RADS (v.1) and PI-RADS (v.2) had no significant effect ($p > 0.05$) on the cancer detection rates (59.0% vs. 66.4%). Two hundred and fifteen (83.3%) of the 258 detected PCas were classified \geq ISUP Grade 2 and thus clinically relevant. Cancer detection rate in patients with PI-RADS 3, 4 and 5 lesions was 45.1% (14/31), 62.2% (107/172) and 93.7% (59/63), respectively (Table 3). Overall cancer detection rate in biopsy naïve patients and patients with repeat biopsies was 70.1% (199/284) and 50.9% (59/116), respectively ($p < 0.01$).

Discussion

One of the primary objectives of this study was to evaluate the tolerability of TP PBx performed under an LA in an office-based setting. In our series, TP PBx under an LA was tolerated well, which is reflected by the low median pain score of 2. Furthermore, more than half of the men who had previously undergone TR PBx rated the TP approach as less painful, whilst about one third of these men reported no difference in regard to perceived discomfort. The low levels of pain are also attributed to the single puncture and the trocar-like access sheath. This technique diminishes trauma to the perineum as compared with the use of templates or grids with multiple entry points. Other studies using similar access systems also reported the feasibility of TP PBx under an LA [15, 16]. We need to highlight that in our series, TP PBx under an LA was performed by an experienced surgeon. Personal patient counselling before, during and after the procedure is indispensable and plays an important role for successful performance.

The second primary objective of this work was to assess the safety of TP PBx in terms of infectious complications with and without periprocedural antibiotic prophylaxis. After our initial experience in 118 patients with 2 doses of antibiotic prophylaxis and no occurrence of infectious complications, we started administering only a single dose of antibiotic prophylaxis in the next 105 men and we finally completely omitted antibiotics in 177 patients. None of the patients in the complete series developed any infectious complications. We assume that the two single entry points and our trocar-like access sheath diminish tissue trauma and, through the avoidance of passage of the biopsy needle through the rectal wall, bacterial exposure. These results suggest that TP PBx requires no antibiotic prophylaxis, although the current guidelines of the American Urological Association and the European Association of Urology both recommend periprocedural antibiotic prophylaxis for TR PBx. Moreover, the European commission recently issued a ruling to no longer use fluoroquinolones as prophylaxis for

PBX due to associated severe side effects. As we are also facing increasing rates of infectious complications due to multidrug resistant bacteria [20], our technique of TP PBX represents an effective method to eliminate infectious complications and, as a direct consequence, to reduce the cost for their treatment. In addition, the reduced use of antibiotics eliminates the risk of antibiotic-related complications and minimises the development of drug resistant bacteria.

Importantly, our series also demonstrates that general or spinal anaesthesia is not required for the performance of TP PBX. Conducting TP PBX under an LA significantly simplifies the procedure and makes TP PBX a feasible in-office procedure. This could lead to a more widespread application. Last year's cancer registry data from Australia and New Zealand demonstrate an increasing use of perineal biopsies with already 23% of biopsies performed via a TP approach [21]. A similar trend can be observed in the UK, where PCa diagnosis was confirmed by perineal biopsy in approximately 12% of all biopsies [22]. These and our data point to a trend towards an increased use of the TP PBX, following the obvious advantages of this approach. The application of this cheap and save method in an outpatient setting also yields an enormous potential for health care savings, given the fact that estimated more than 1 million prostate biopsies are performed annually in the US [4]. Moreover, to use our technique of TP PBX in an LA, standard urological office equipment can be used and no other sophisticated devices or software based biopsy systems are needed.

Previous studies demonstrated comparable diagnostic results of TR PBX and TP PBX in terms of cancer detection rates [14, 19, 23]. The applied freehand MRI/US cognitive fusion TP PBX yielded an overall cancer detection rate of 64.5%, which is slightly higher than the cancer detection rates reported elsewhere [14, 19, 23]. The significantly lower overall cancer detection rate in patients who had undergone prior biopsy (50.9%), as compared with biopsy naïve patients (70.1%), is most likely due to the fact that these patients have elevated PSA levels due to benign prostatic lesions, such as benign prostate hyperplasia (BPH) or chronic inflammatory disease. In particular, the high cancer detection rate of 93.7% in cases with PI-RADS 5 highlights the diagnostic precision of this method in the hands of an experienced surgeon. In our view, this technique requires the ability to precisely read mpMRI in order to create a three-dimensional view of the prostate, as well as experience in ultrasound-guided PBX. Given these prerequisites, and most urologists have these capabilities, comparable cancer detection rates should be reproducible in any urological office.

This study is limited due to its retrospective design, the single centre data and the lack of an adequate control group.

Nevertheless, this work contributes to the mounting body of evidence demonstrating the feasibility, safety and patients' tolerability of TP PBX under an LA. The advantages of omitting peri-procedural antibiotic prophylaxis, the elimination of infectious complications and the high diagnostic accuracy make this approach very appealing for the application in any urological office.

In conclusion, freehand TP PBX in an LA is a safe, effective and well-tolerated outpatient procedure with a high cancer detection rate. The elimination of infectious complications combined with its high accuracy make this technique a feasible alternative to the TR approach for the urological office. We assume that the single puncture and our trocar-like access sheath introduction technique contribute to these results.

Acknowledgements The authors want to thank Dr Selina Ackermann from the University Hospital Basel for editorial assistance.

Compliance with ethical standards

Conflict of interest The authors declare that they have no conflict of interest.

Publisher's note Springer Nature remains neutral with regard to jurisdictional claims in published maps and institutional affiliations.

References

1. Heidenreich A, Bastian PJ, Bellmunt J, Bolla M, Joniau S, van der Kwast T, et al. EAU guidelines on prostate cancer. Part 1: screening, diagnosis, and local treatment with curative intent-update 2013. *Eur Urol.* 2014;65:124–37.
2. Litwin MS, Tan HJ. The diagnosis and treatment of prostate cancer: a review. *JAMA.* 2017;317:2532–42.
3. Liu W, Patil D, Howard DH, Moore RH, Wang H, Sanda MG, et al. Adoption of prebiopsy magnetic resonance imaging for men undergoing prostate biopsy in the United States. *Urology.* 2018; 117:57–63.
4. Loeb S, Carter HB, Berndt SI, Ricker W, Schaeffer EM. Complications after prostate biopsy: data from SEER-Medicare. *J Urol.* 2011;186:1830–4.
5. Borghesi M, Ahmed H, Nam R, Schaeffer E, Schiavina R, Taneja S, et al. Complications after systematic, random, and image-guided prostate biopsy. *Eur Urol.* 2017;71:353–65.
6. Loeb S, van den Heuvel S, Zhu X, Bangma CH, Schroder FH, Roobol MJ. Infectious complications and hospital admissions after prostate biopsy in a European randomized trial. *Eur Urol.* 2012; 61:1110–4.
7. Pepdjonovic L, Tan GH, Huang S, Mann S, Frydenberg M, Moon D, et al. Zero hospital admissions for infection after 577 transperineal prostate biopsies using single-dose cephazolin prophylaxis. *World J Urol.* 2017;35:1199–203.
8. Symons JL, Huo A, Yuen CL, Haynes AM, Matthews J, Sutherland RL, et al. Outcomes of transperineal template-guided prostate biopsy in 409 patients. *BJU Int.* 2013;112:585–93.
9. Altok M, Kim B, Patel BB, Shih YT, Ward JF, McRae SE, et al. Cost and efficacy comparison of five prostate biopsy modalities: a

- platform for integrating cost into novel-platform comparative research. *Prostate Cancer Prostatic Dis.* 2018;21:524–32.
10. Gross MD, Shoag JE, Hu JC. Is in-office transperineal biopsy the future of prostate cancer diagnosis? *Curr Opin Urol.* 2019;29:25–26.
 11. Zimmerman ME, Meyer AR, Carter HB, Allaf ME, Gorin MA. In-office transperineal prostate biopsy using biplanar ultrasound guidance: a step-by-step guide. *Urology.* 2019;133:247.
 12. Dimmen M, Vlatkovic L, Hole KH, Nesland JM, Brennhovd B, Axcrona K. Transperineal prostate biopsy detects significant cancer in patients with elevated prostate-specific antigen (PSA) levels and previous negative transrectal biopsies. *BJU Int.* 2012;110(2 Pt 2):E69–75.
 13. Mabweesh NJ, Lidawi G, Chen J, German L, Matzkin H. High detection rate of significant prostate tumours in anterior zones using transperineal ultrasound-guided template saturation biopsy. *BJU Int.* 2012;110:993–7.
 14. Stefanova V, Buckley R, Flax S, Spevack L, Hajek D, Tunis A, et al. Transperineal prostate biopsies using local anesthesia: experience with 1287 patients. Prostate cancer detection rate, complications and patient tolerability. *J Urol.* 2019;201:1121–6.
 15. Meyer AR, Joice GA, Schwen ZR, Partin AW, Allaf ME, Gorin MA. Initial experience performing in-office ultrasound-guided transperineal prostate biopsy under local anesthesia using the precisionpoint transperineal access system. *Urology.* 2018;115:8–13.
 16. Thurtle D, Starling L, Leonard K, Stone T, Gnanapragasam VJ. Improving the safety and tolerability of local anaesthetic outpatient transperineal prostate biopsies: a pilot study of the CAMbridge PROstate Biopsy (CAMPROBE) method. *J Clin Urol.* 2018;11:192–9.
 17. Emiliozzi P, Longhi S, Scarpone P, Pansadoro A, DePaula F, Pansadoro V. The value of a single biopsy with 12 transperineal cores for detecting prostate cancer in patients with elevated prostate specific antigen. *J Urol.* 2001;166:845–50.
 18. Dindo D, Demartines N, Clavien PA. Classification of surgical complications: a new proposal with evaluation in a cohort of 6336 patients and results of a survey. *Ann Surg.* 2004;240:205–13.
 19. Xue J, Qin Z, Cai H, Zhang C, Li X, Xu W, et al. Comparison between transrectal and transperineal prostate biopsy for detection of prostate cancer: a meta-analysis and trial sequential analysis. *Oncotarget.* 2017;8:23322–36.
 20. Carignan A, Roussy JF, Lapointe V, Valiquette L, Sabbagh R, Pepin J. Increasing risk of infectious complications after transrectal ultrasound-guided prostate biopsies: time to reassess antimicrobial prophylaxis? *Eur Urol.* 2012;62:453–9.
 21. Evans SMTG, Brooks A, Currow D, Davis ID, Delprado W, Frizelle F, et al. Prostate cancer outcomes registry-Australia and New Zealand Report 2018. Reporting on data 2015–2016. Melbourne, VIC: Monash University & The Movember Foundation; 2018.
 22. National Prostate Cancer Audit. Results of the NPCA prospective audit in England and Wales for men diagnosed from 1 April 2016 to 31 March 2017. National Prostate Cancer Audit. London: The Royal College of Surgeons of England.
 23. Grummet J, Pepdjonovic L, Huang S, Anderson E, Hadaschik B. Transperineal vs. transrectal biopsy in MRI targeting. *Transl Androl Urol.* 2017;6:368–75.